JHGD
Journal of Human Growth and Development

www. jhgd.com.br

ORIGINAL ARTICLE

Clinical Application of G21 Polyamide Membrane in Guided Bone Regeneration in the Pre-Dental Implant Region: Case Report

Renan Nogueira da Costa[a], Luis Carlos de Lara[b], Adilson Sakuno[c], Marcus Paulo Ferreira Barbosa[d], Vinycius Lima Pereira[e], Eduardo Velozo da Silva[f], Luis Mille Monteiro de Sousa[g], Valdelias Xavier Pereira[h]

Open acess

[a] Mestrando em Implantodontia UNISA – Professor do curso de especialização em Implantodontia APCD

[b] Coordenador Cientifico em Desenvolvimento de Biomateriais Materplastic

[c] Professor Doutor da Faculdade de odontologia da APCD – Coordenador dos cursos de especialização em Implantodontia FAOA e Schetinni Educação Continuada Recife

[d] Mestrando em Implantodontia UNISA – Professor dos cursos de especialização em Implantodontia FAOA e Schetinni Educação Continuada Recife

[e] Especialista em Ortopedia e Ortodontia dos Maxilares – Pesquisador Laboratório de Delineamento de Estudo e Escrita Cientifica da LDEEC/FMABC

[f] Mestre em Prótese pela Faculdade São Leopoldo Mandic – Doutorando em Implantodontia São Leopoldo Mandic – Professor do curso de especialização em Implantodontia FAOA-APCD.

[g] Pesquisador. Programa de Pós-Graduação em Nutrição e Saúde na Universidade Federal do Espírito Santo.

[h] Professor Doutor. Centro Universitário FMABC – Pesquisador Laboratório de Delineamento de Estudo e Escrita Cientifica da LDEEC/FMABC – Especialização em Implantodontia da FAOA-APCD

Corresponding author
valdeliasxavierpereira@gmail.com

Manuscript received: may 2025
Manuscript accepted: december 2025
Version of record online: august 2025

Abstract

Introduction: Guided Bone Regeneration (GBR) is a technique that uses membranes as physical barriers to promote new bone formation in defect areas, preventing soft tissue invasion. The G21 dental regenerative membrane, composed of non-resorbable polyamide, presents promising characteristics, such as biocompatibility, impermeability, and structural stability.

Objective: to evaluate the clinical efficacy of the G21 membrane in alveolar preservation after extraction for dental implant placement.

Method: this is a prospective clinical case report involving a 43-year-old male patient who underwent extraction of the upper right first molar with extensive periradicular lesion. The G21 membrane was installed immediately after extraction and removed after 15 days. Clinical and radiographic follow-up was performed in three phases: preoperative, immediate postoperative (15 days), and late postoperative (80 days), focusing on bone formation and viability for dental implant placement.

Results: the G21 membrane demonstrated excellent clinical integration, with no signs of inflammation or rejection. Granulation tissue formation was evident at 15 days, and new bone formation was confirmed by imaging after 80 days. Clinical application proved straightforward, without the need for further surgery to remove the membrane.

Conclusion: the G21 polyamide membrane demonstrated satisfactory results in guided bone regeneration, demonstrating a viable, safe, and effective alternative for clinical use in alveolar preservation without the use of grafts.

Keywords: guided tissue regeneration, bone substitutes, nylons, biocompatible materials.

Suggested citation: Costa RN, Lara LC, Sakuno A, Barbosa MPF, Pereira VL, Silva EV, Sousa LMM, Pereira VX. Clinical Application of G21 Polyamide Membrane in Guided Bone Regeneration in the Pre-Dental Implant Region: Case Report. *J Hum Growth Dev. 2025; 35(2):306-313.* DOI: http://doi.org/10.36311/jhgd.v35.17786

Authors summary

Why was this study done?
The study was conducted to evaluate the clinical efficacy of a new non-resorbable polyamide membrane (G21) in guided bone regeneration (GBR), focusing on preserving the tooth socket after extraction. The researchers sought viable, safe, and graft-free alternatives to facilitate future implant placement.

What did the researchers do and find?
They applied the G21 membrane to a patient after extraction of a molar with a periradicular lesion.
They monitored the case clinically and radiographically in three phases: before surgery, 15 days after surgery, and 80 days after surgery.
They removed the membrane within 15 days without the need for further surgery.

What do these findings mean?
The findings indicate that the G21 membrane is an efficient and safe alternative for clinical use in guided bone regeneration, offering good results in socket preservation and enabling future implant placement without the need for additional grafts or surgeries to remove the membrane.

INTRODUCTION

Guided Bone Regeneration (GBR) was introduced as a therapeutic modality that seeks the neoformation of resorbed bone tissue through the use of membranes[1]. The concept of GBR was established based on the principle of guided tissue regeneration, where certain tissues regenerate when cells with this capacity populate the defect during healing[2].

The function of the membrane is to act as a physical barrier that prevents the migration of epithelial cells and connective tissue into the bone defect, while allowing osteogenic cells to stimulate bone tissue formation. Thus, many biodegradable and non-biodegradable materials have been used in the manufacture of regenerative membranes. Regardless of the type of material, regenerative membranes must exhibit biocompatibility (regulated in Brazil through NBR ISO 10993), integration with host tissues, clinical manageability, and the ability to maintain space[3].

Non-biodegradable membranes are frequently used for periodontal and bone regeneration[4], although they require a second surgical procedure for removal. On the other hand, biodegradable materials, although absorbable by the body and not requiring another intervention, have limitations in maintaining the physical barrier due to the membrane's gradual degradation.

One type of membrane used in GBR (Guided Bone Regeneration) is the G21 Polyamide Membrane, a non-biodegradable material used in bone regeneration and the stabilization of dental implants. Its characteristics include impermeability and biocompatibility, which prevent microbial growth and the absorption of food residues, thus supporting Guided Bone Regeneration techniques. To ensure the microbiological safety of the product, it is necessary to determine the average microbial load according to the methods described in ISO 11737-1 (Sterilization of medical devices – Microbiological methods – Part 1: Determination of the population of microorganisms on product). This analysis must be carried out for each batch and for all samples, resulting in the total average microbial load. This control is conducted internally by the company Materplastic through a Bioburden study, ensuring the microbiological quality of the material[5].

METHODS

Study Design

The study is characterized as a prospective clinical case report, focusing on the evaluation of the efficacy and safety of the G21 dental regenerative membrane (polyamide-based) in Guided Bone Regeneration (GBR) techniques.

The study phases include: Single intervention - Implantation of the G21 membrane after immediate extraction of element 16 (first upper right molar); Sequential monitoring - Clinical and imaging evaluations (radiographs and computed tomography) in the preoperative phase (analysis of the bone defect), immediate postoperative phase (15 days: membrane removal and analysis of granulation tissue) and late postoperative phase (80 days: evaluation of bone formation and viability for implant installation); and Internal comparison - Analysis of bone regeneration without the use of grafts or bone substitutes, using only the blood clot stabilized by the physical barrier (membrane).

Study Location and Period

Performed at a dental clinic in São Paulo, Brazil, under the responsibility of dentist Dr. Renan Nogueira da Costa (CRO-SP 116445).

The follow-up period began with the primary intervention on May 10, 2023, when tooth #16 was extracted, followed by the immediate implantation of the G21 regenerative membrane. The second stage occurred on May 25, 2023, corresponding to the 15th postoperative day, when the membrane was removed and the granulation tissue was assessed. Finally, on July 29, 2023, equivalent to 80 days after the initial surgery, the final evaluation was performed using clinical and imaging examinations, thus concluding the case's monitoring cycle.

Study Population and Eligibility Criteria

A single participant was a 43-year-old male, classified as having normal system function. The patient had a formal indication for extraction of the upper right first molar (tooth 16) due to the presence of an extensive periradicular lesion and the impossibility of endodontic retreatment. The inclusion criteria were the need to preserve the alveolar ridge immediately after extraction and the absence of active infectious processes

in the surgical region. In addition to the absence of known hypersensitivity to the components of polyamide (as per the manufacturer's contraindications), a history of systemic comorbidities that compromise the regenerative cascade—such as uncontrolled diabetes mellitus or states of immunosuppression—as well as active smoking habits or the use of anti-angiogenic drugs, due to their potential to interfere with tissue repair processes.

Data Analysis

The data were evaluated using descriptive methods, focusing on the direct observation of clinical and imaging results in relation to granulation tissue and new bone formation.

Assessment of bone formation, measured by computed tomography (bone thickness, ridge height, and density); Clot integrity, in relation to the stability of the surgical site and absence of early membrane exposure; Complications, with records of inflammation, infection, or rejection, by means of panoramic radiographs, parasagittal and multiplanar tomographic sections, and 3D reconstructions.

Clinical success criteria were painless membrane removal within 15 days and absence of inflammatory signs. Functional success criteria included the feasibility of implant placement within 80 days (bone drilling without complications).

Ethical and Legal Aspects of Research

The polyamide film is manufactured by an approved supplier and is used exclusively by Materplastic for the production of dental regenerative membranes, having undergone rigorous biocompatibility testing. The biomaterial has been submitted for notification to ANVISA (National Health Surveillance Agency), as it meets the biocompatibility requirements of ISO 10993. It is submitted through a technical dossier with risk analysis, mitigating any risk of incompatibility with humans.

According to NBR ISO 10993-1, the Biocompatibility studies were completed, and the product was classified as low risk (Class II). Therefore, there is no need for Clinical studies, according to art. 3 of RDC of February 10, 2015 – Regularization of clinical trials with medical devices in Brazil.

Therefore, the reports are sufficient to prove Biocompatibility and will be attached to this report proving the veracity of the facts:

1. According to the Analysis report RL2232502CT, carried out by the certified laboratory ALS, the Dental Regenerative Membrane - G21 sample did not present a toxic effect on the L-929 cell line, therefore it was not considered cytotoxic.

2. According to the Analysis report RL2232500IMO, carried out by the certified laboratory, under the test conditions, the dental regenerative membrane sample-G21 was considered non-irritating to the oral mucosa of Syrian hamsters (Mesocricetus auratus).

3. According to the Analysis Report RL2232501LLNA, performed by the ALS-certified laboratory, under the test conditions, the Dental Regenerative Membrane - G21 sample presented a borderline positive result (SI between 1.6 and 1.9). Therefore, additional information was considered, as evidence of systemic toxicity. The animals did not show clinical signs of systemic toxicity.

The procedure strictly followed the ethical and legal precepts applicable to research involving human subjects and dental practice. Based on the Dental Code of Ethics and CNS Resolution 466/2012, the procedure ensured an assessment of risks and benefits. The biomaterial (polyamide G21) was used after satisfactory completion of biocompatibility studies, an essential step to ensure the minimum safety required before human exposure. The patient, duly informed of the nature of the new biomaterial and the procedure, provided free and informed consent, thus respecting the principle of autonomy. The technical execution was performed exclusively by a qualified dental surgeon (Dr. Renan Nogueira da Costa, CRO-SP 116445), in accordance with the legal attributions of the profession. The entire process ensured respect for the participant's dignity and compliance with good clinical practice guidelines.

CASE PRESENTATION

The 43-year-old male patient, of color He was white and classified as normosystem, living in the Brazilian state of São Paulo. He presented with intense pain when chewing and an increase in volume in the vestibular region of the upper right first molar (tooth 16). The tooth in question had previously undergone endodontic treatment and reconstruction with prefabricated posts cemented into the canals with resin cement. The tooth still presented an extensive apical lesion, and endodontic retreatment was not foreseeable. Therefore, we opted for extraction of the tooth (on May 10, 2023) and alveolar preservation with the G21 membrane.

In cases of alveolar preservation with injury, the use of bone grafts is not indicated due to the possibility of contamination of the biomaterial at the site, therefore the use of the G21 dental regenerative membrane is indicated, with the aim of preserving the site to favor the formation and stability of the blood clot through the ROG technique - Guided Bone Regeneration.

Application of the G21 Dental Regenerative Membrane

After completion of the biocompatibility studies, followed by the extraction of element 16, the G21 polyamide dental regenerative membrane was implanted in the patient and kept in place for 15 days.

Figure 1 : clinical appearance before (a) and after (b) extraction of element 16.

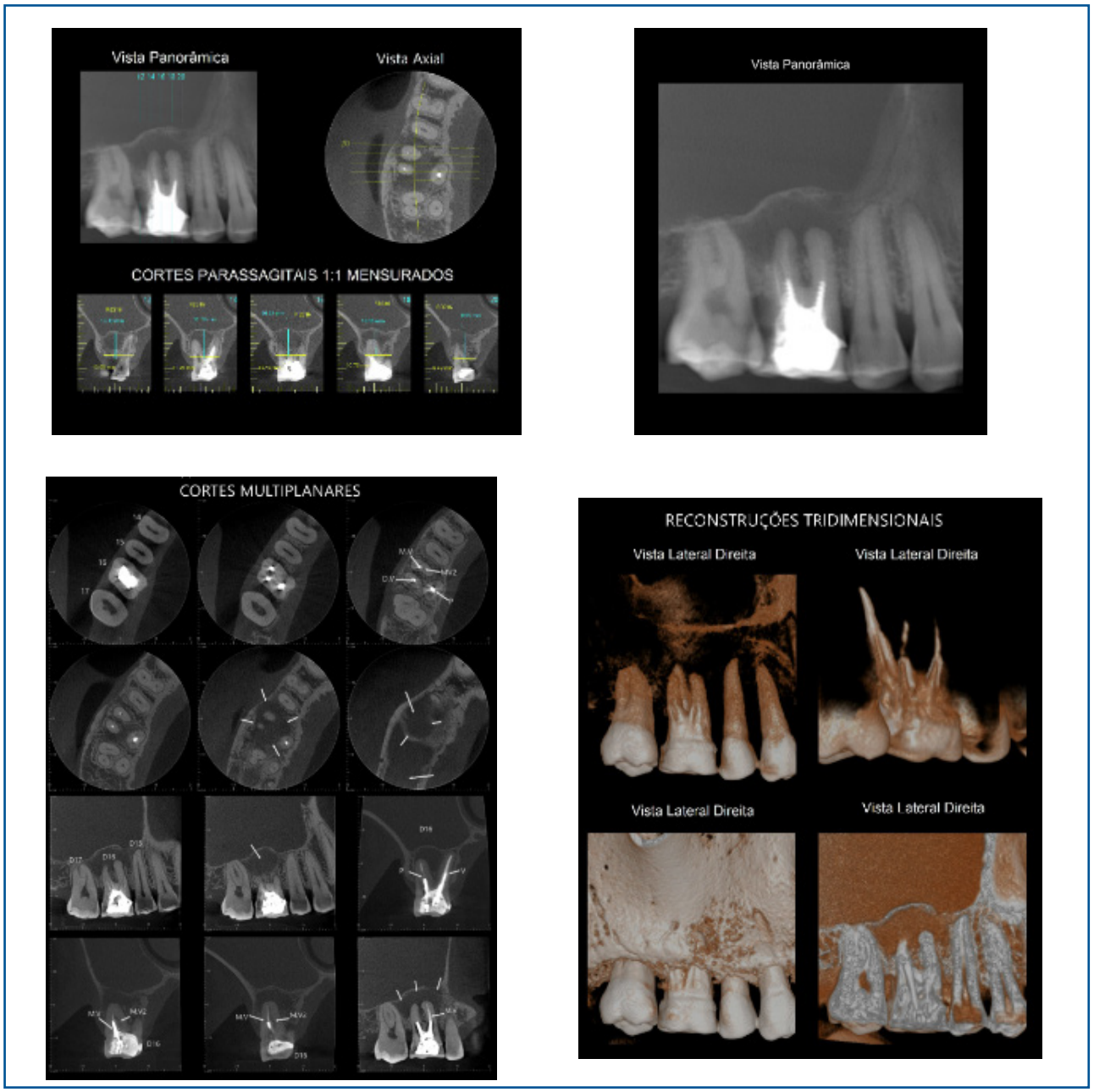

Figure 2 : Radiographic appearance of element 16, before extraction: parasagittal, axial, panoramic view (ab), multiplanar (c), and three-dimensional (d) sections.

Figure 3 : clinical aspect of the region after application of the G21 membrane.

The G21 polyamide membrane was used as shown in Figure 3, offering high predictability of bone regeneration. The polyamide film was constructed with a smooth top, mitigating the risk of bacterial contamination, and is impermeable to solutions and food in the oral environment.

The patient was monitored during the membrane implantation period, and no inflammatory reactions were observed that would justify its removal.

Removal of the G21 dental regenerative membrane, after 15 days

After the seventh day, the clot was replaced with granulation tissue, allowing the regenerative membrane to be removed. However, we opted to wait 15 days for this tissue to mature.

The dental regenerative membrane was removed 15 days after the initial implantation, in a simple and painless way that did not require further surgery or local anesthesia. The suture thread was removed and the membrane was removed with the aid of sterile tweezers.

Figure 4 : Clinical images after membrane removal, and formation of granulation tissue, bone formation.

Patient after 80 days of initial surgery

After the osteogenesis period was completed, the patient returned to the office, and the results were satisfactory, the expected formation occurred and we began the procedure for drilling the hole for the dental implant (Figures 5 and 6).

Analysis of the imaging results demonstrates the formation of newly formed bone tissue, indicating that the goal of Guided Bone Regeneration (GBR) was successfully achieved with the use of the new polyamide membrane, even in the absence of grafts or bone substitutes. The G21 regenerative dental membrane demonstrated satisfactory performance in relation to the fundamental criteria for this type of approach, including biocompatibility, space maintenance, cell exclusion, structural integrity, and appropriate clinical management. Furthermore, its application effectively contributed to promoting osteogenesis at the treated site.

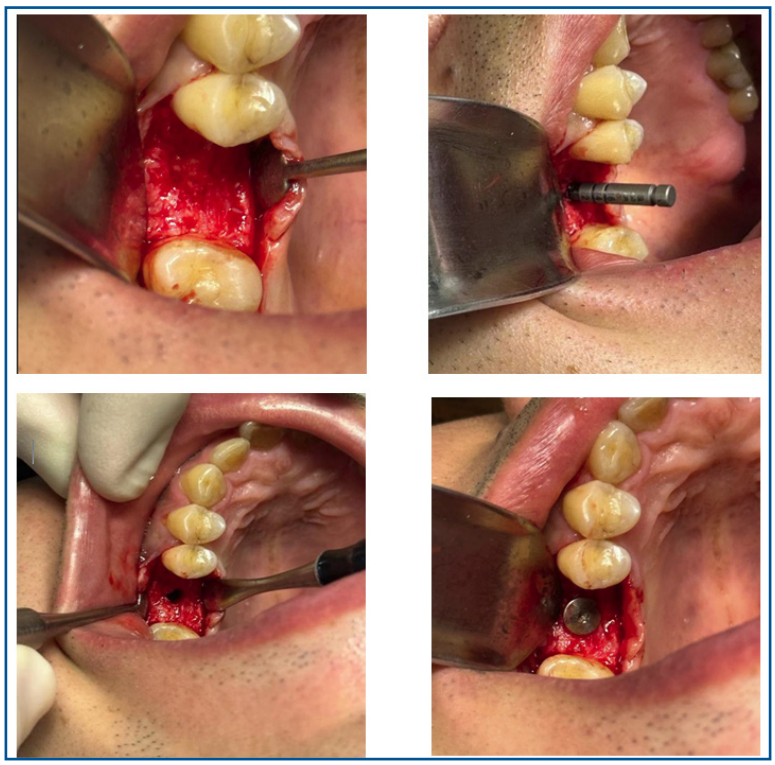

Figure 5: Osteogenic formation after 80 days and implant installation.

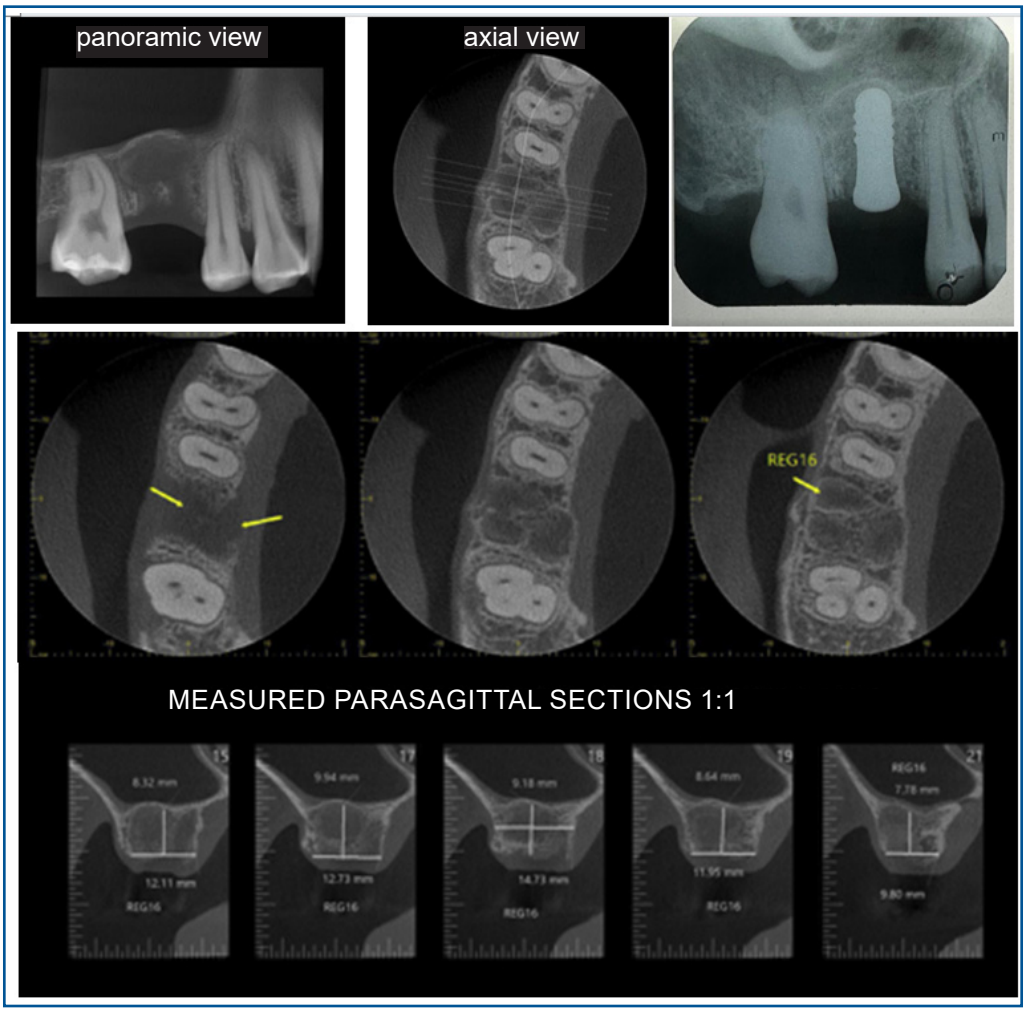

Figures 6: radiographic aspects after extraction and 80-day evolution, in panoramic, axial and parasagittal views.

DISCUSSION

The G21 dental regenerative membrane, after meeting the regulatory biocompatibility requirements, demonstrates clinical applicability in post-extraction cases, alveolar wall defects, immediate implants, small bone fenestrations and bone expansion procedures to increase thickness when bone marrow is present between the vestibular/palatal or vestibular/lingual cortices.

As established in the literature 6 , the blood clot is a fundamental element in the healing of the residual alveolar ridge, requiring preservation at the extraction site. However, studies show progressive alveolar resorption in short- and long-term analyses, making the maintenance of alveolar architecture critical for adequate functional and aesthetic rehabilitation[7-8].

The Guided Bone Regeneration (GBR) technique employed allowed physiological preservation of the ridge dimensions without the use of grafts or bone substitutes. The alveolus was filled exclusively with blood clot and protected by the physical barrier of the G21 membrane, with imaging documentation demonstrating the formation of granulation tissue as a precursor stage of osteogenesis. As reported in previous studies, the osteogenic process begins immediately through clot organization, with complete bone maturation occurring within 90 days postoperatively, a period during which the membrane effectively prevented microbial contamination even after exposure to the oral environment[9].

Analysis of the polyamide's properties indicated satisfactory biocompatibility, with no evidence of cytotoxic effects or adverse tissue reactions in peri-implant tissues, recognizing that no implantable material exhibits absolute inertia. Its optimized thickness provides adequate rigidity for maintaining the regenerative space, resisting masticatory compressive forces without structural collapse, a crucial factor for preserving newly formed bone volume.

The effectiveness of cell exclusion was confirmed by the absence of fibrous connective tissue formation by epithelial migration, while the porous microarchitecture allowed selective diffusion of biological fluids and bioactive mediators, creating a microenvironment favorable to angiogenesis and osteoprogenitor differentiation.

CONCLUSION

The material's thickness proved ideal for clinical handling, allowing for precise cutting, shaping, and adjustment to the bone defect area without the need for secondary surgical removal—a distinct advantage over other membranes available on the Brazilian market. Additionally, the G21 membrane exhibited excellent biocompatibility, effectively preventing microbial contamination and maintaining its integrity because it is non-resorbable.

Its stability was essential for the success of guided bone regeneration, as demonstrated by the results presented. Although the study did not monitor the final osseointegration phase of the implants, it achieved its primary objective: to validate the efficacy and safety of the G21 regenerative membrane, which is suitable for introduction into the Brazilian dental market.

Author Contributions

All authors contributed to the execution and development stages of this work.

Funding

This study did not receive financial support from public or private institutions.

Conflicts of Interest

The authors declare no conflicts of interest related to the development of this research.

REFERENCES

1. Lazarevic M, Petrovic S, Pierfelice TV, Ignjatovic N, Piattelli A, Vlajic Tovilovic T, et al. Antimicrobial and osteogenic effects of collagen membrane decorated with chitosan-nano-hydroxyapatite. Biomolecules [Internet]. 2023 Mar 23;13(4):579. Available from: http://dx.doi.org/10.3390/biom13040579
2. Tessarolo GD, Gonçalves V, Langa WA de O, Peçanha MM, Almeida LGR de. Alveolar preservation approaches after tooth extraction - a literature review. Braz J Hea Rev [Internet]. 2024 Nov 4;7(9):e74238. Available from: http://dx.doi.org/10.34119/bjhrv7n9-003
3. Cortelli JR, Lotufo RF, Oppermann RV, Sallum AW, Costa FO. Glossary of the Brazilian society of periodontology. Rev Periodontia. 2005 December;15(4):5-61. SciELO RevOdonto - revodonto.bvsalud.org [Internet]. [cited 2025 Jul 23]. Available from: http://revodonto.bvsalud.org/scielo.php?script=sci_nlinks&ref=080427&pid=S1806-146X201000010001000002&lng=pt
4. Di Stefano DA, Orlando F, Ottobelli M, Fiori D, Garagiola U. A comparison between anorganic bone and collagen-preserving bone xenografts for alveolar ridge preservation: systematic review and future perspectives. Maxillofac Plast Reconstr Surg [Internet]. 2022 [cited 2025 Jul 2];44(1):24. https://doi.org/10.1186/s40902-022-00349-3
5. Fiorillo L, D'amico C, Milone D, Cervino G. Preservation of bone volume in implant-supported post-extraction sockets: Tissue conditioning during prosthetic rehabilitation. In: ASEC 2023 [Internet]. Basel Switzerland: MDPI; 2023. p. 51. Available from: http://dx.doi.org/10.3390/ASEC2023-15320
6. Pires ALR, Bierhalz ACK, Moraes ÂM. Biomaterials: Types, applications, and market. Quim Nova [Internet]. 2015;38(7):957–71. Available from: http://dx.doi.org/10.5935/0100-4042.20150094

7. Ali M, Mohd Noor SNF, Mohamad H, Ullah F, Javed F, Abdul Hamid ZA. Advances in guided bone regeneration membranes: a comprehensive review of materials and techniques. Biomed Phys Eng Express [Internet]. 2024 Apr 17;10(3). Available from: http://dx.doi.org/10.1088/2057-1976/ad1e75
8. Karring T, Nyman S, Gottlow J, Laurell L. Development of the biological concept of guided tissue regeneration--animal and human studies. Periodontol 2000 [Internet]. 1993 Feb;1:26–35. Available from: https://pubmed.ncbi.nlm.nih.gov/9673206/
9. Dahlin C, Linde A, Gottlow J, Nyman S. Healing of bone defects by guided tissue regeneration. Plast Reconstr Surg [Internet]. 1988 May;81(5):672–6. Available from: http://dx.doi.org/10.1097/00006534-198805000-00004

Resumo

Introdução: a Regeneração Óssea Guiada (ROG) é uma técnica que utiliza membranas como barreiras físicas para favorecer a neoformação óssea em áreas de defeito, impedindo a invasão de tecidos moles. A membrana regenerativa odontológica G21, composta por poliamida não reabsorvível, apresenta características promissoras, como biocompatibilidade, impermeabilidade e estabilidade estrutural.

Objetivo: avaliar a eficácia clínica da membrana G21 na preservação alveolar pós-exodontia para instalação de implante dentário.

Método: trata-se de um relato de caso clínico prospectivo envolvendo um paciente do sexo masculino, 43 anos, submetido à extração do primeiro molar superior direito com extensa lesão perirradicular. A membrana G21 foi instalada imediatamente após a exodontia e removida após 15 dias. O acompanhamento clínico e radiográfico foi realizado em três fases: pré-operatória, pós-operatória imediata (15 dias) e tardia (80 dias), com foco na formação óssea e viabilidade para instalação de implante dentário.

Resultados: a membrana G21 demonstrou excelente integração clínica, sem sinais de inflamação ou rejeição. A formação de tecido de granulação foi evidente aos 15 dias, e a neoformação óssea foi confirmada por exames de imagem após 80 dias. A aplicação clínica mostrou-se simples, sem necessidade de nova cirurgia para remoção da membrana.

Conclusão: a membrana de poliamida G21 apresentou resultados satisfatórios na regeneração óssea guiada, demonstrando-se uma alternativa viável, segura e eficaz para uso clínico na preservação alveolar sem o emprego de enxertos.

Palavras-chave: regeneração óssea guiada, biocompatibilidade, poliamida, perda do osso alveolar.

©The authors (2025), this article is distributed under the terms of the Creative Commons Attribution 4.0 International License (http://creativecommons.org/licenses/by/4.0/), which permits unrestricted use, distribution, and reproduction in any medium, provided you give appropriate credit to the original author(s) and the source, provide a link to the Creative Commons license, and indicate if changes were made. The Creative Commons Public Domain Dedication waiver (http://creativecommons.org/publicdomain/zero/1.0/) applies to the data made available in this article, unless otherwise stated.